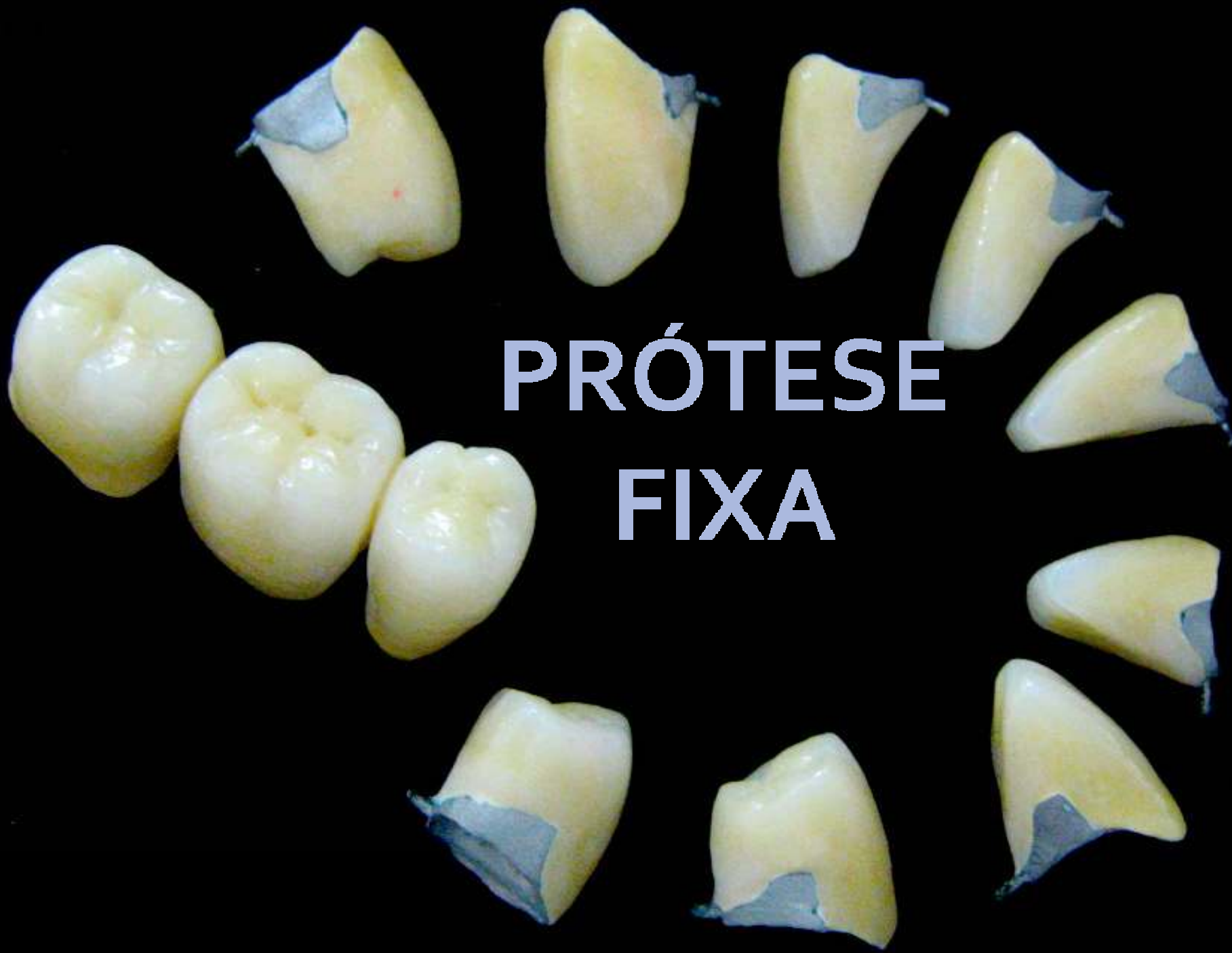


AVISO:

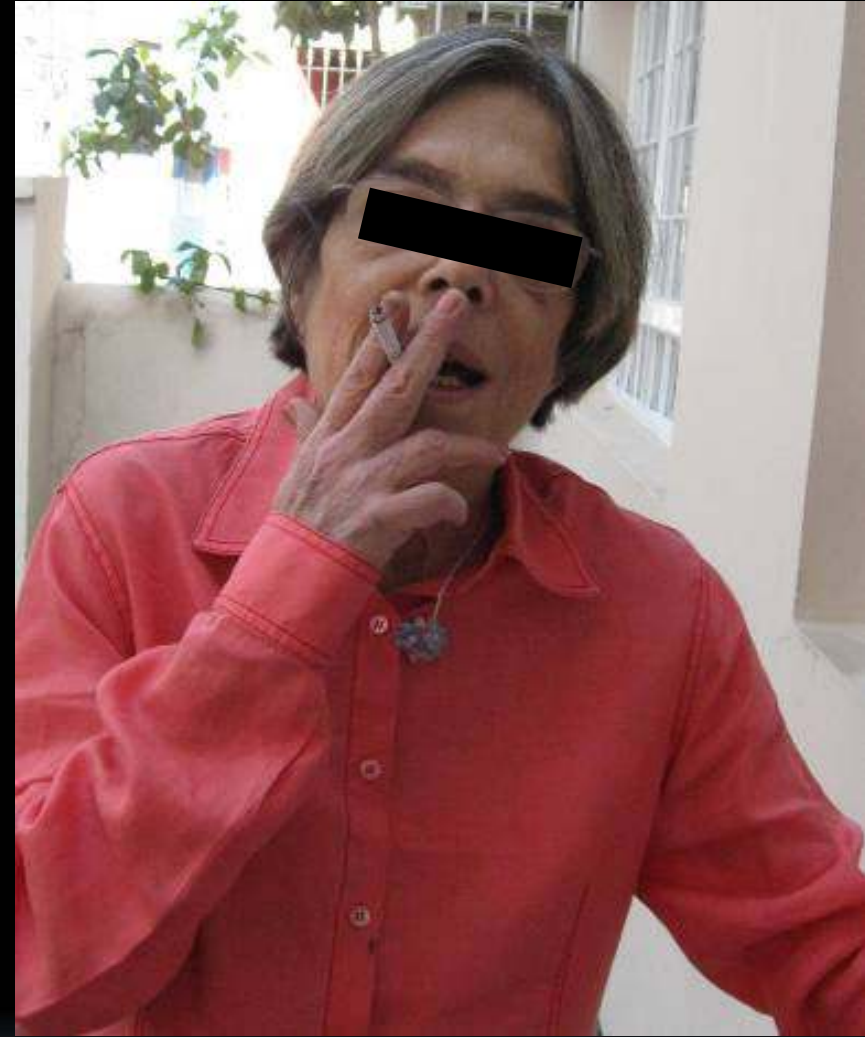O conteúdo do Caso Clínico a seguir foi cedido gentilmente pela *Prof. Cristina Fiuza*, para a publicação no website www.bioart.com.br, sendo a mesma autora e detentora dos “Direitos Autorais” do conteúdo de imagens e textos apresentados a seguir.

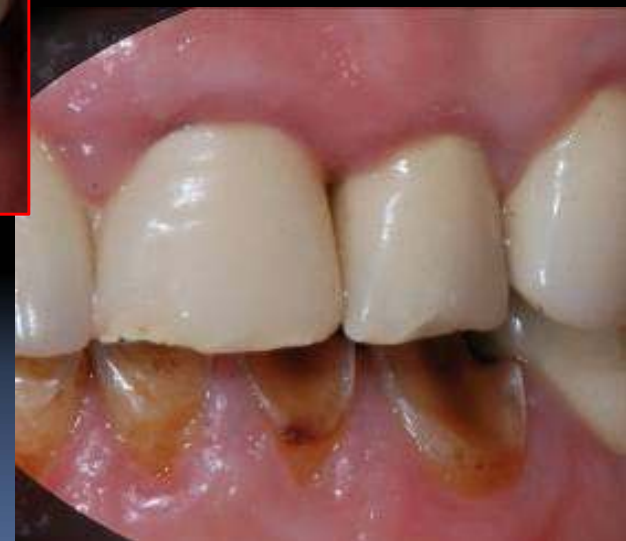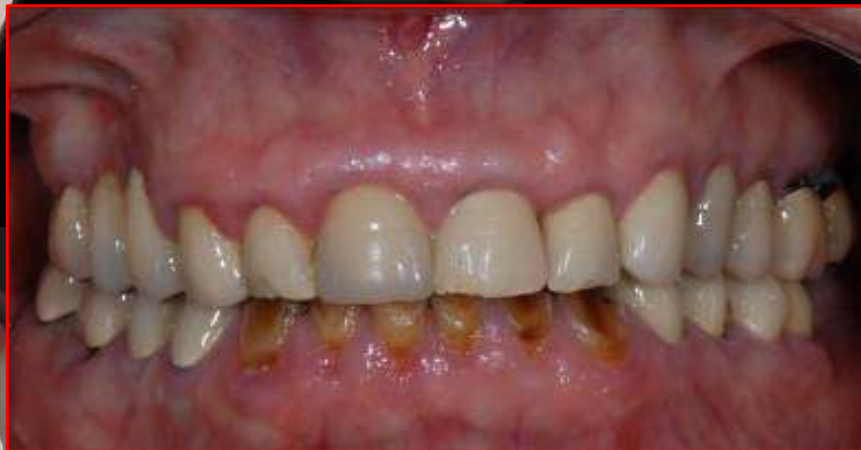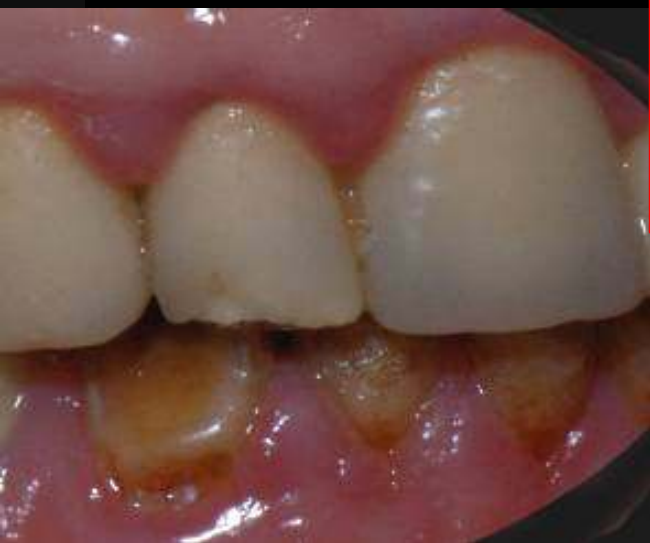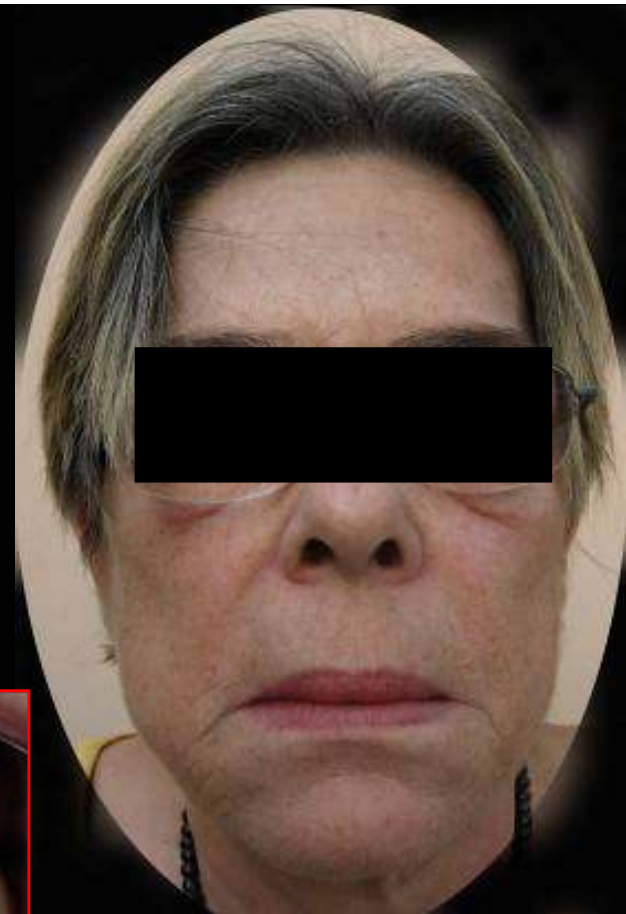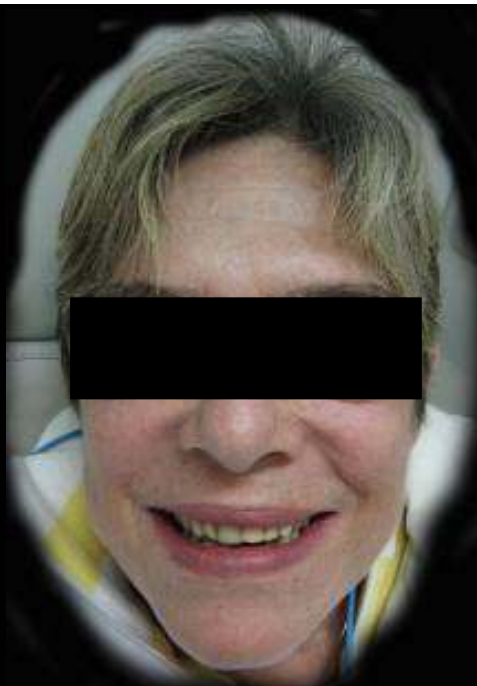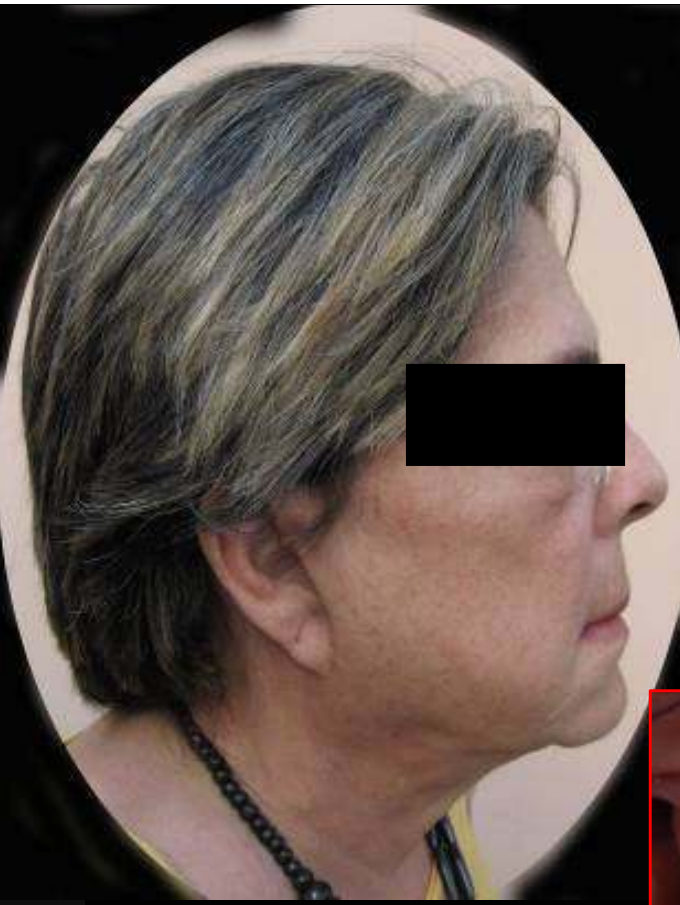Para o esclarecimento de dúvidas e maiores informações escreva para:

cris@fiuza.odo.br



PRÓTESE FIXA

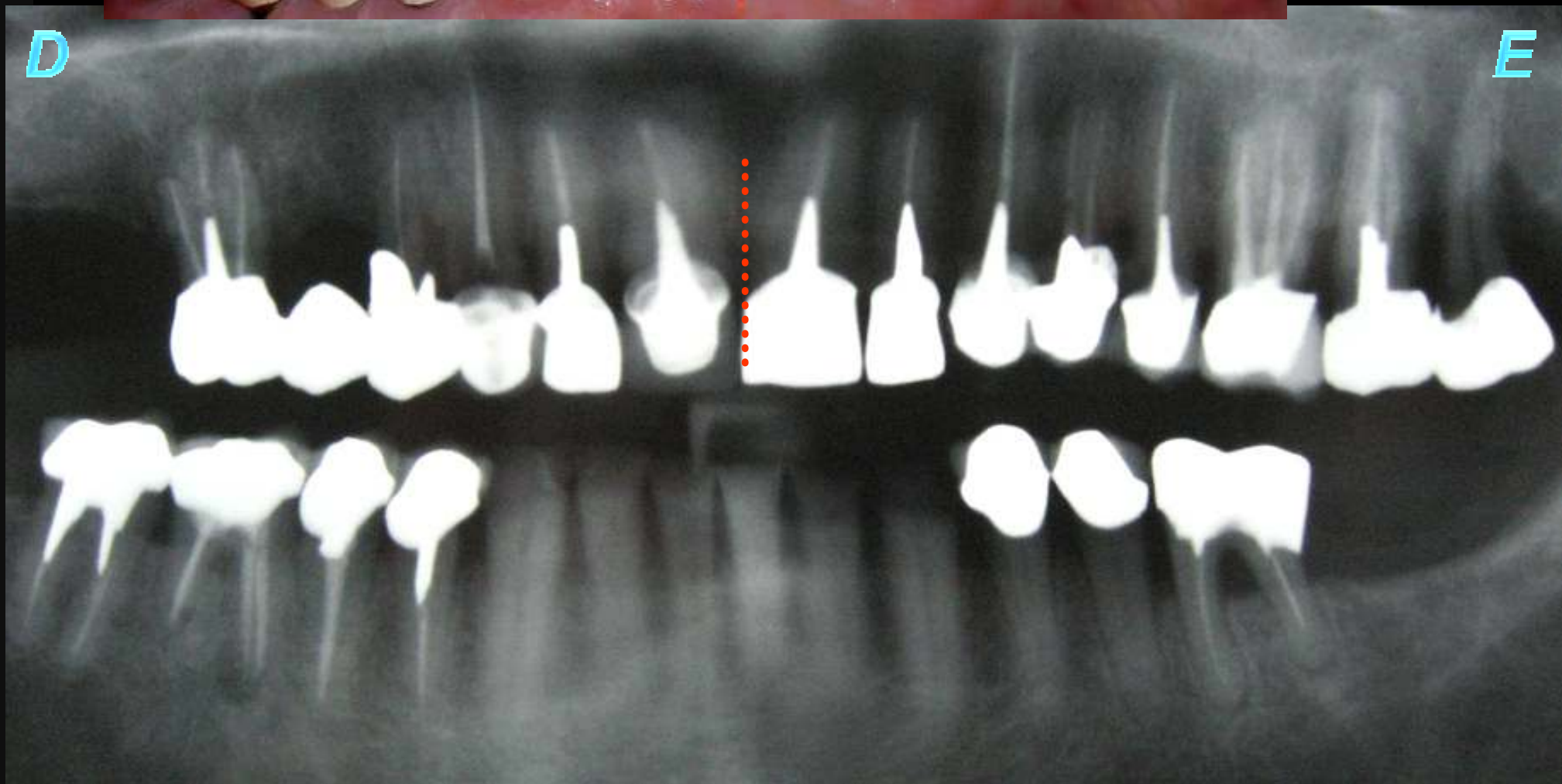
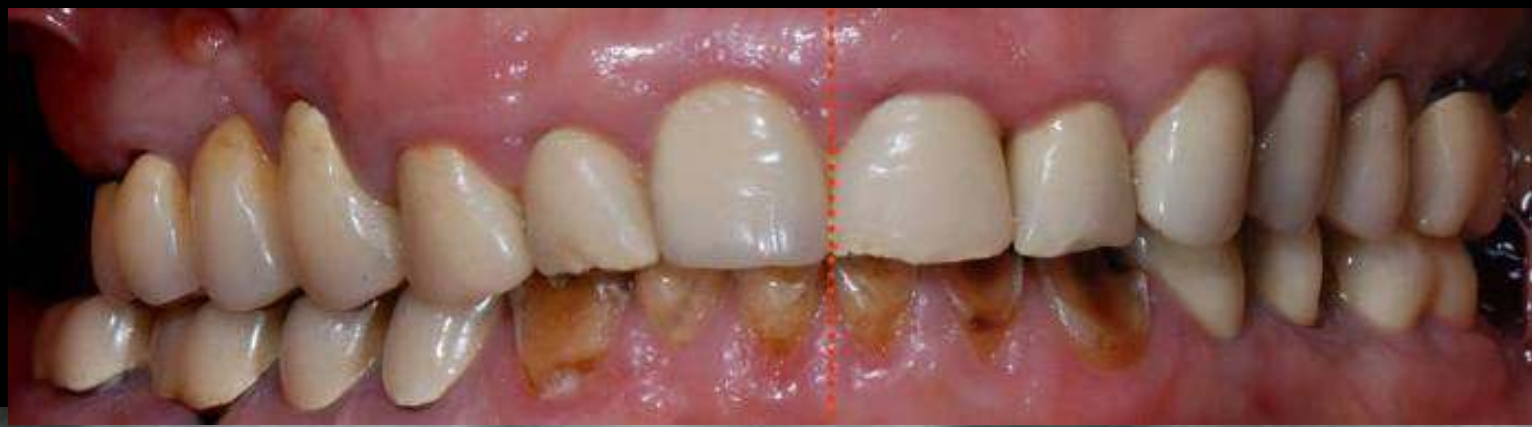
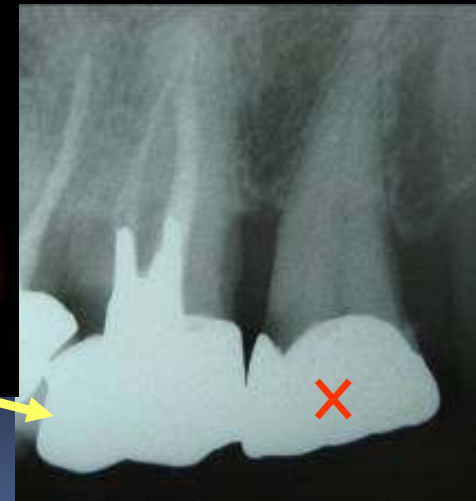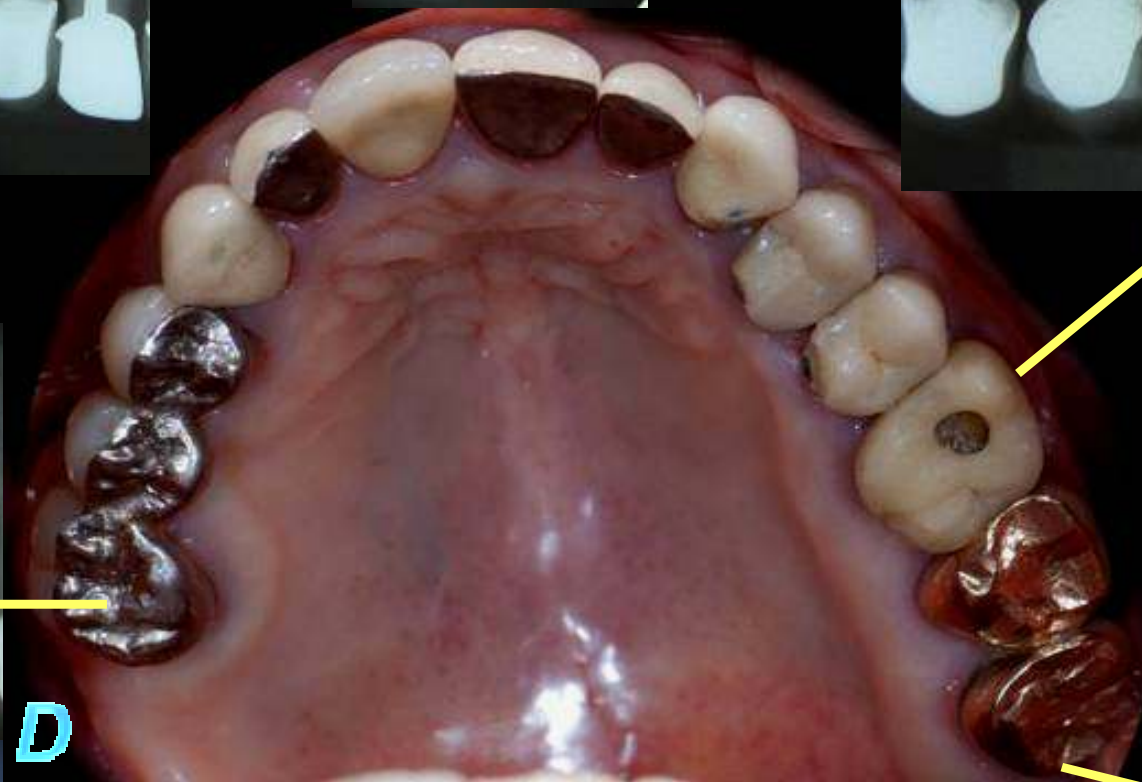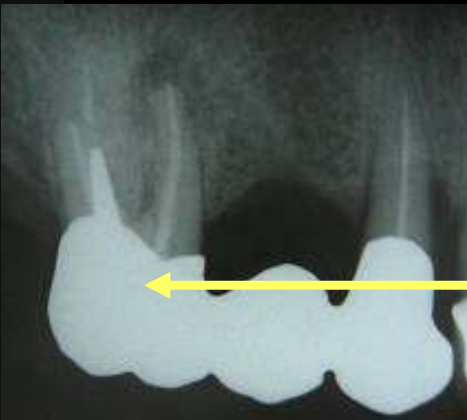
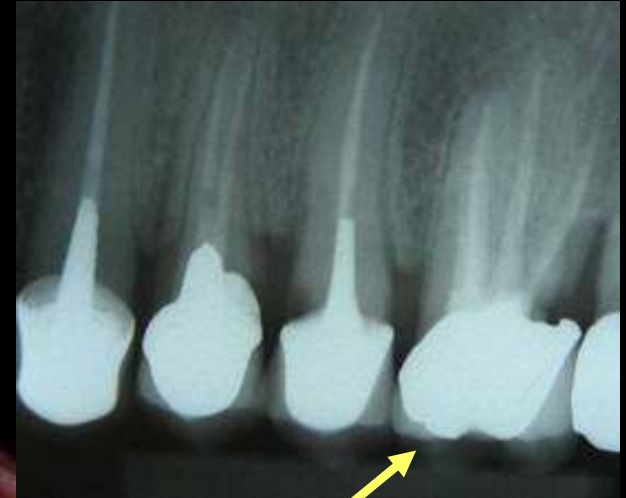


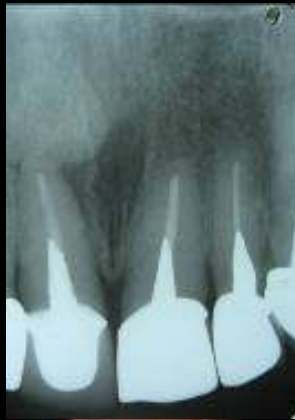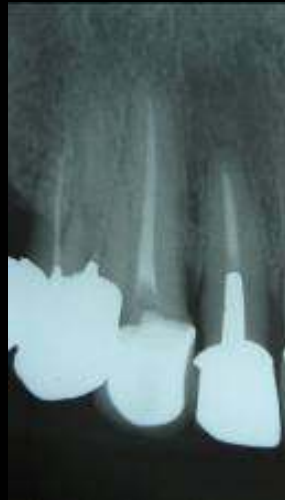Jardim Paulista

CF

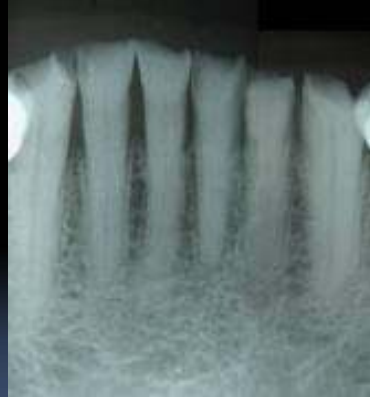
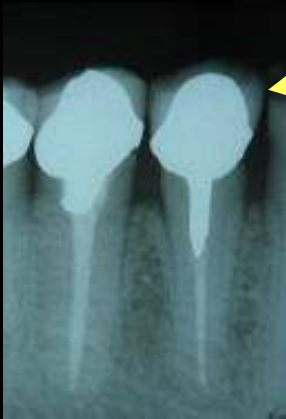
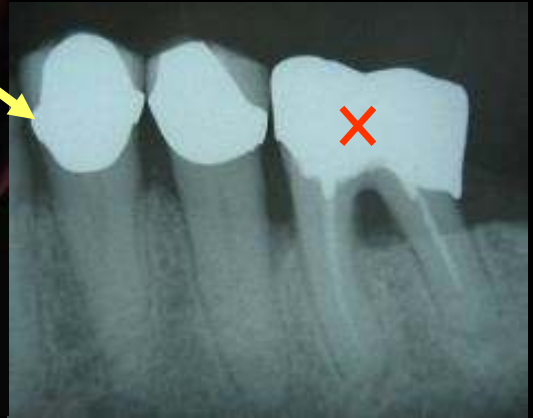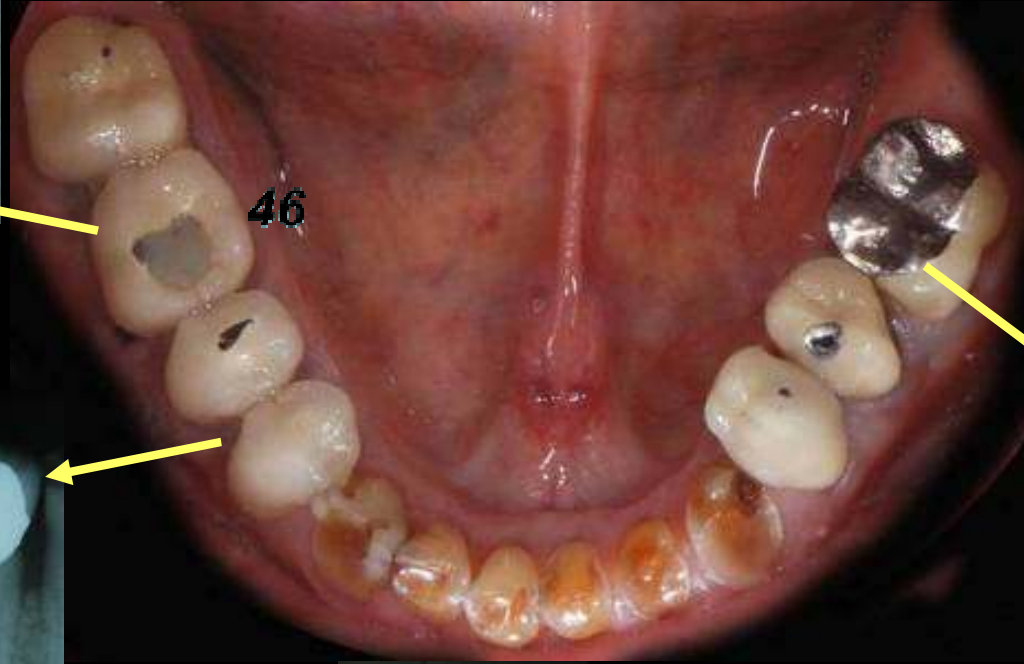
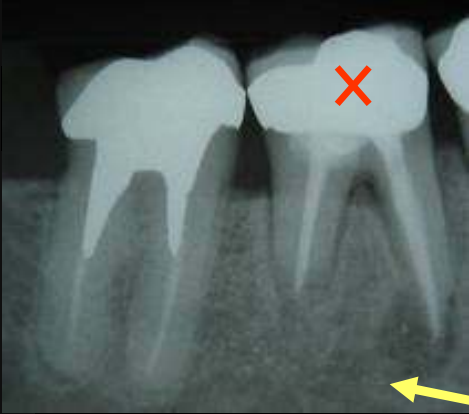
Caso Clínico e Radiográfico - Inicial



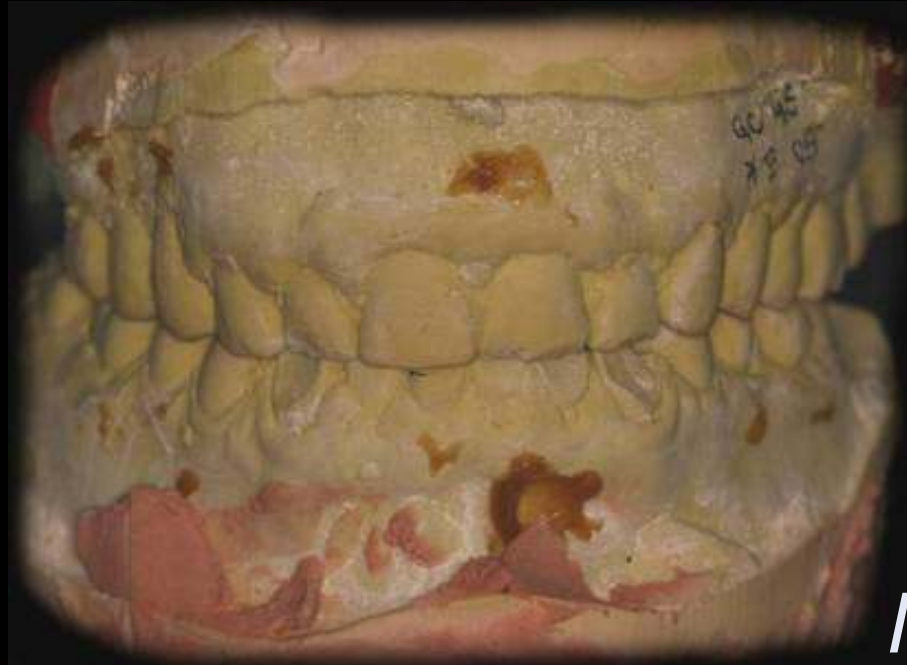

Próteses fixas fraturadas, desgastadas e cáries

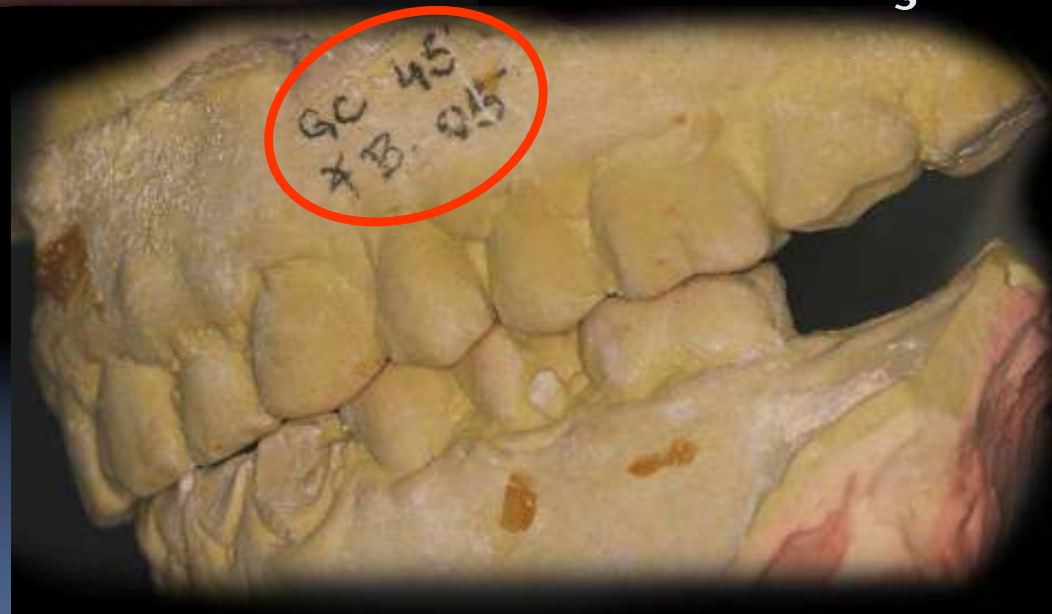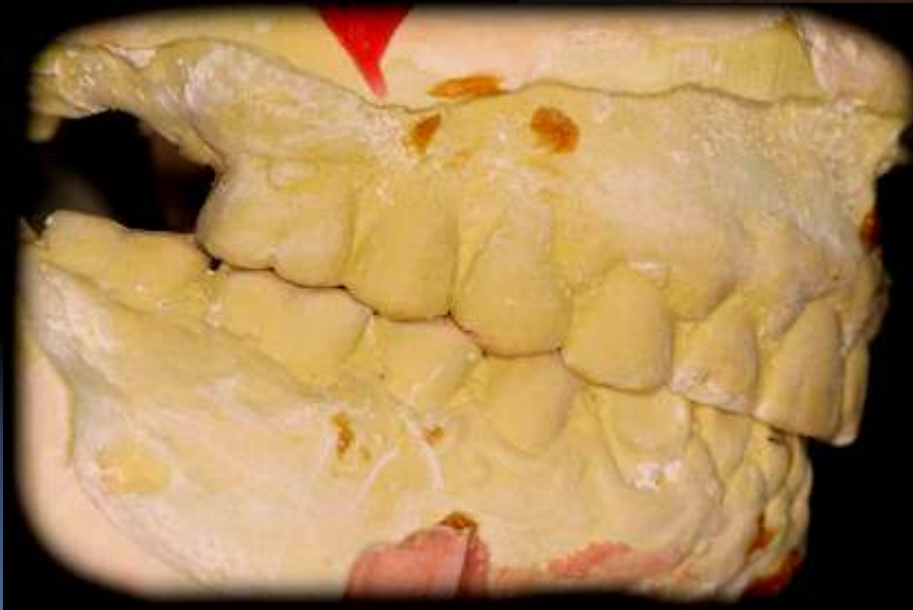D



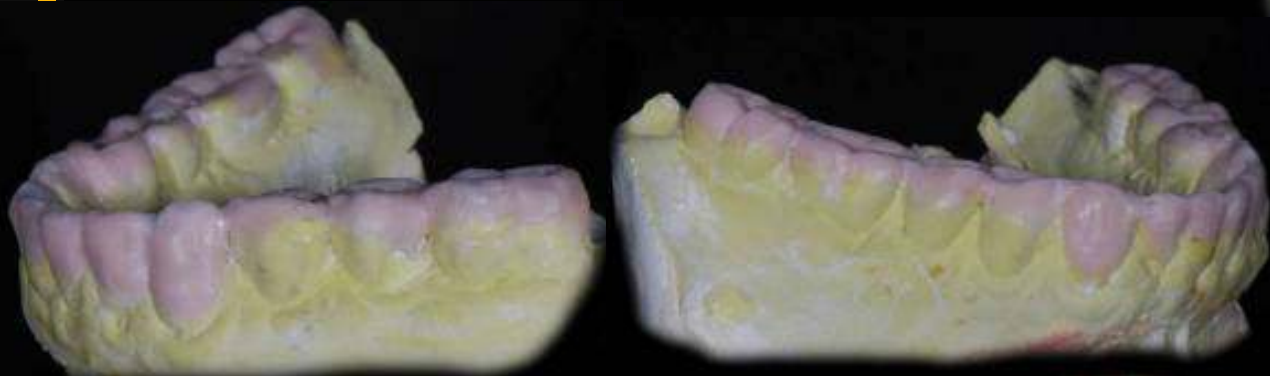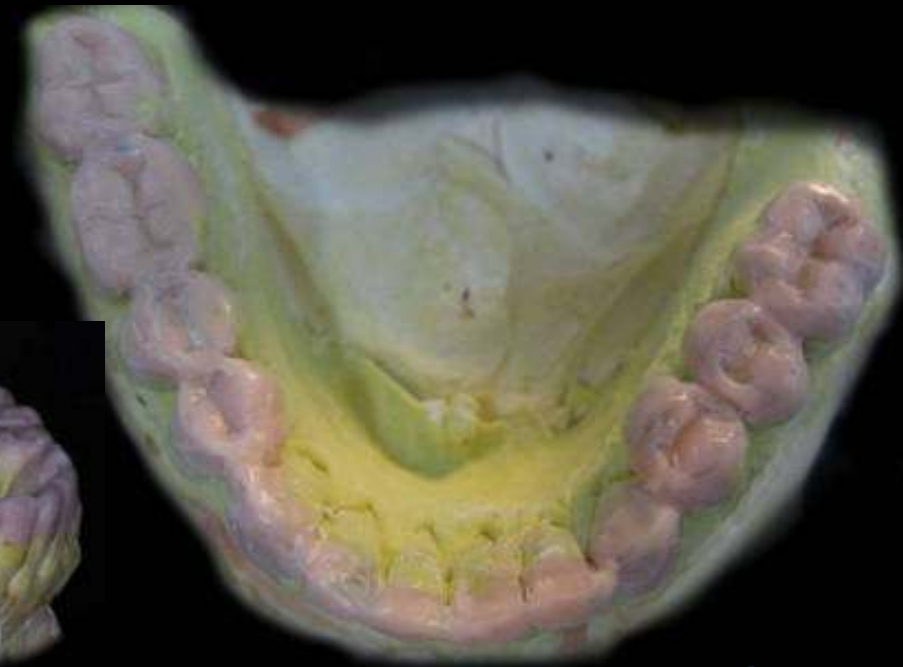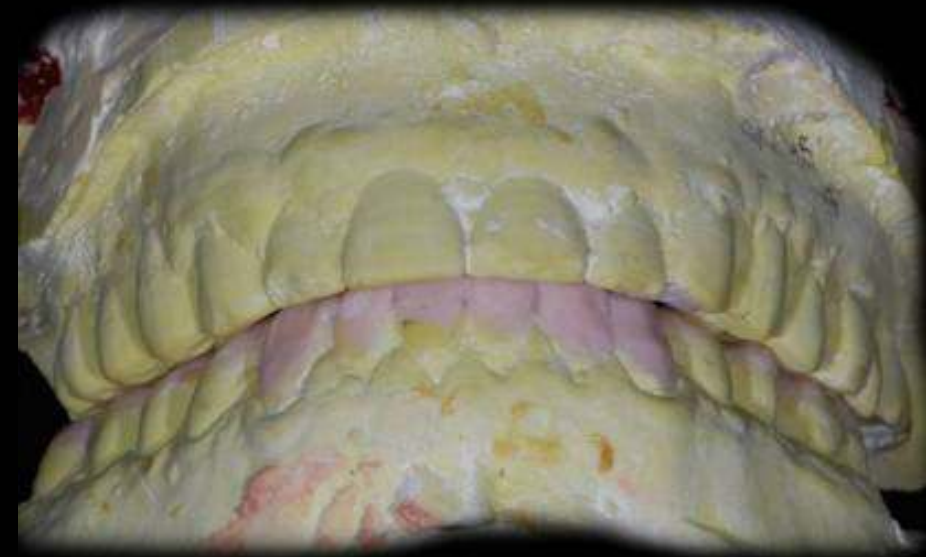Montagem no Articulador em R. C.

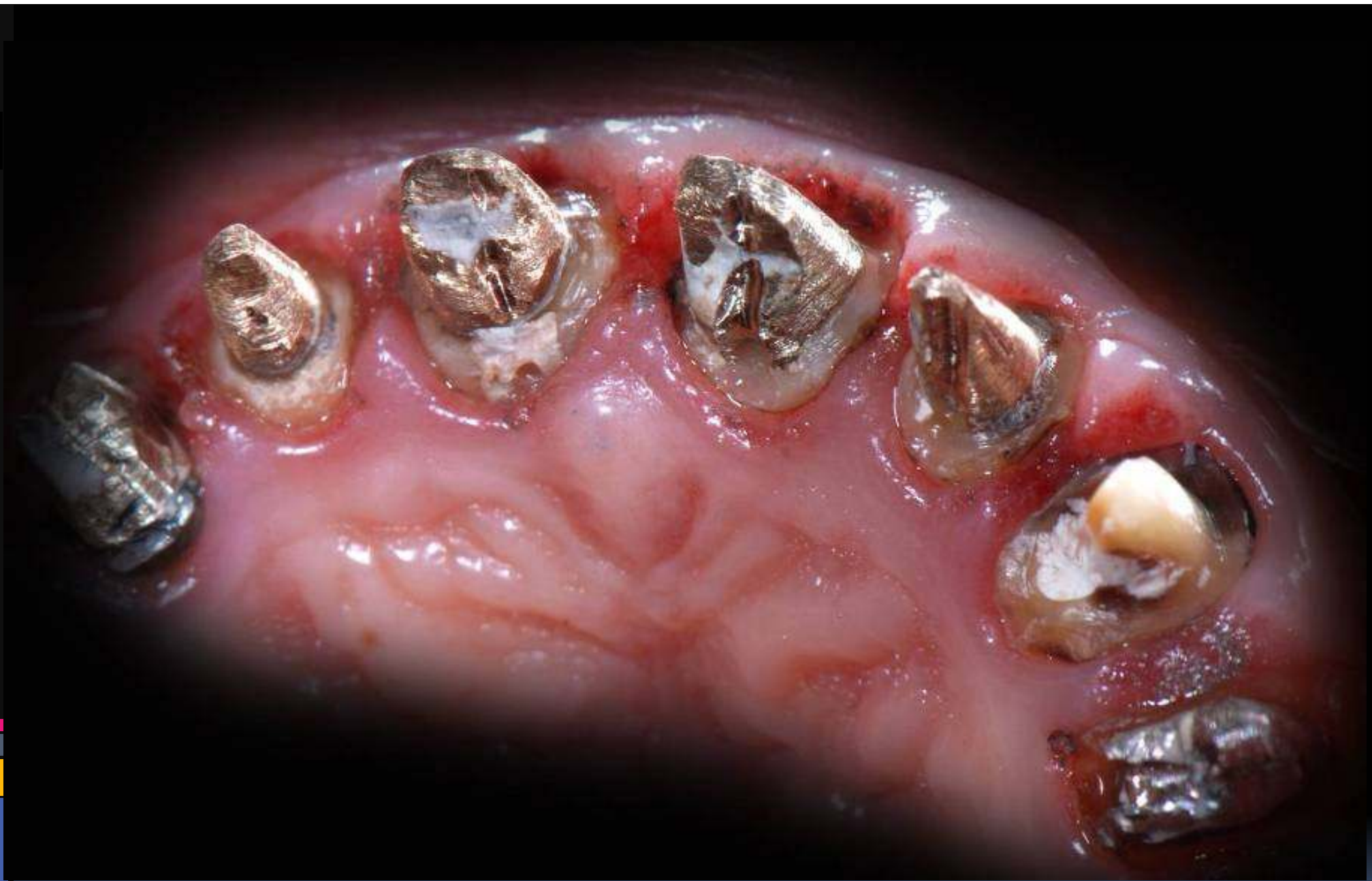

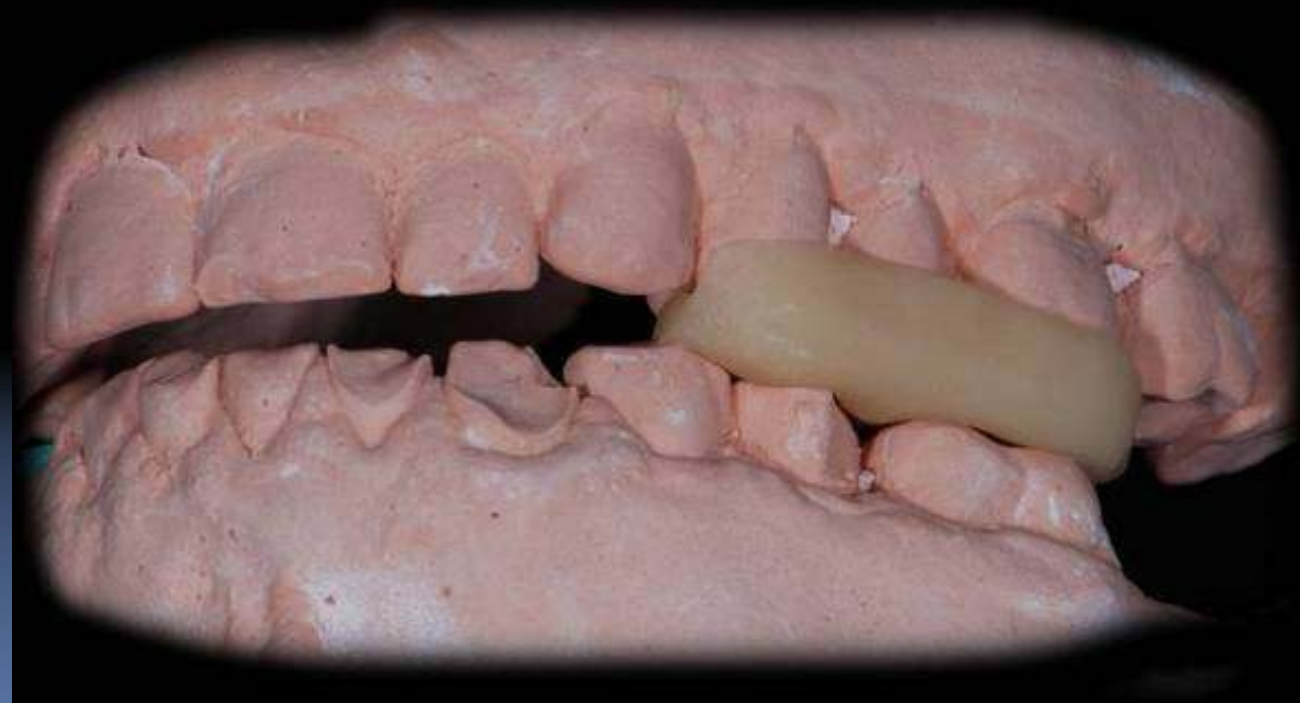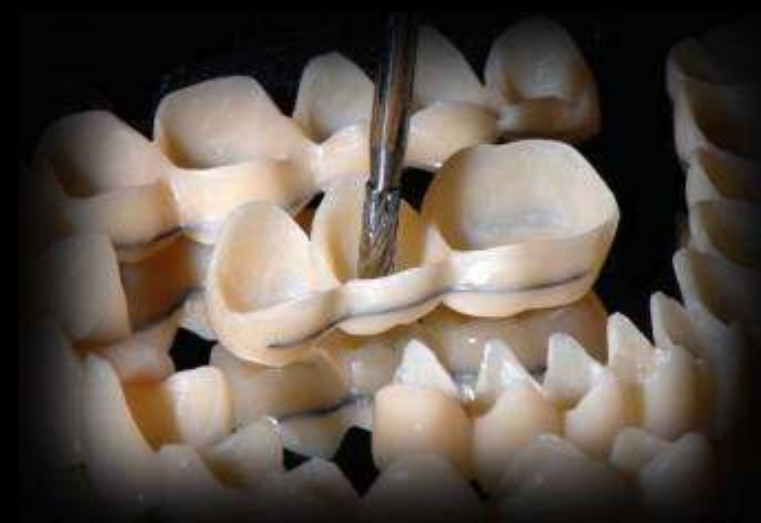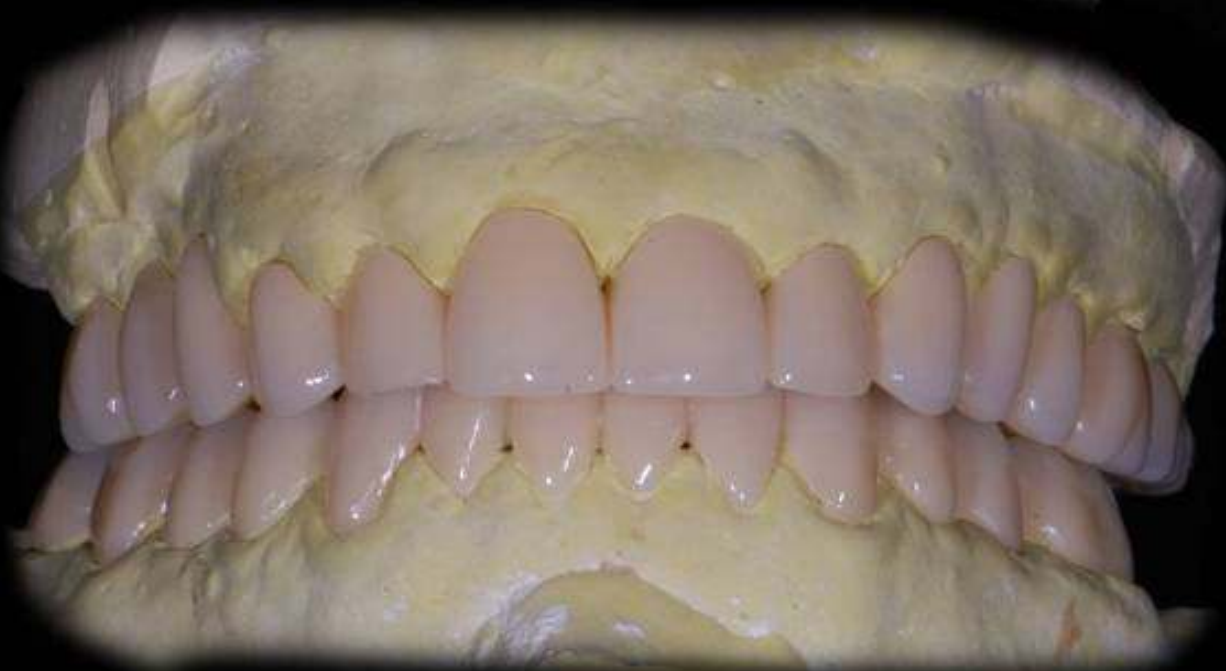Individualizaç^ão



Análise de Broadrick - Enceramento

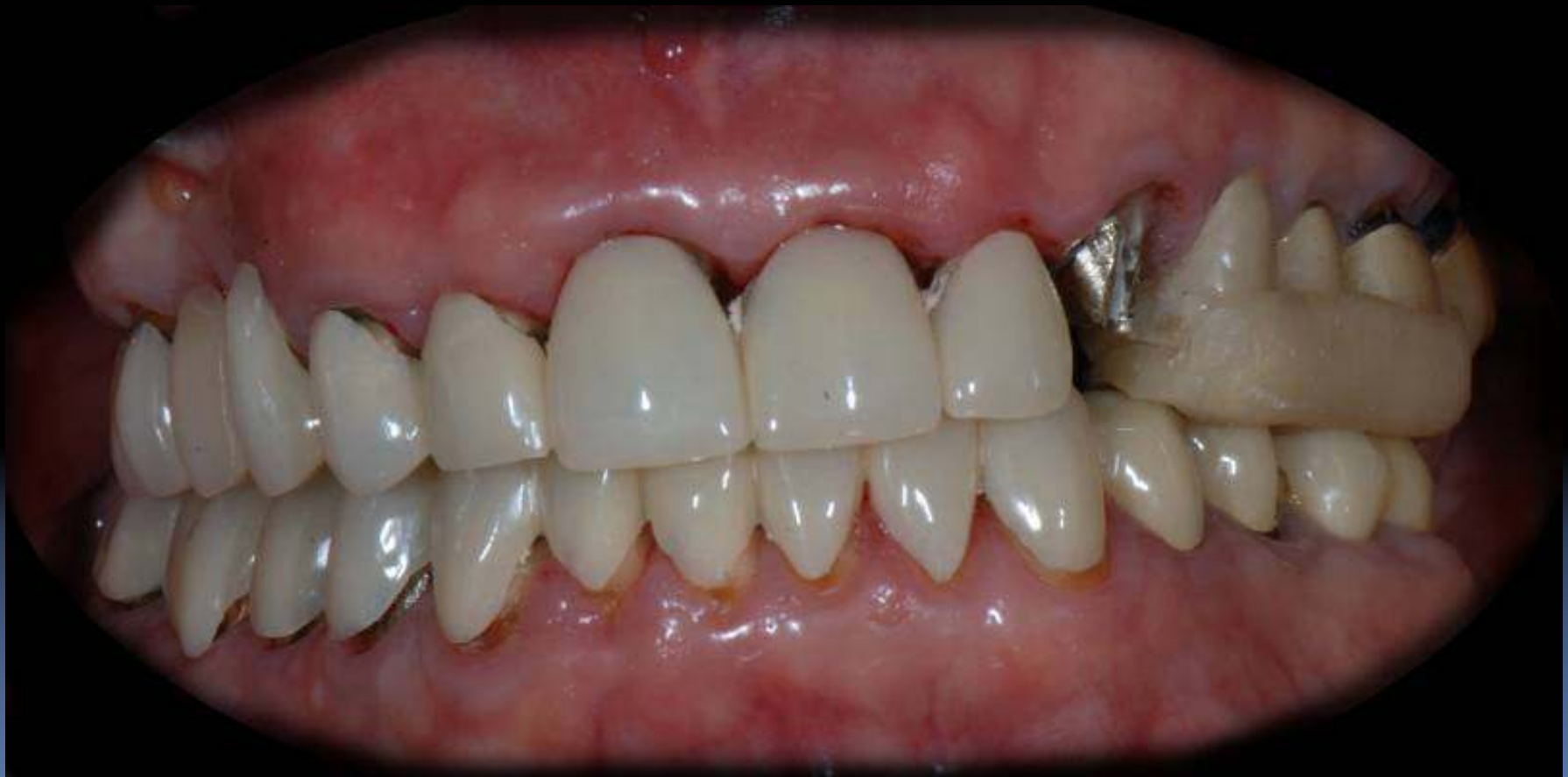
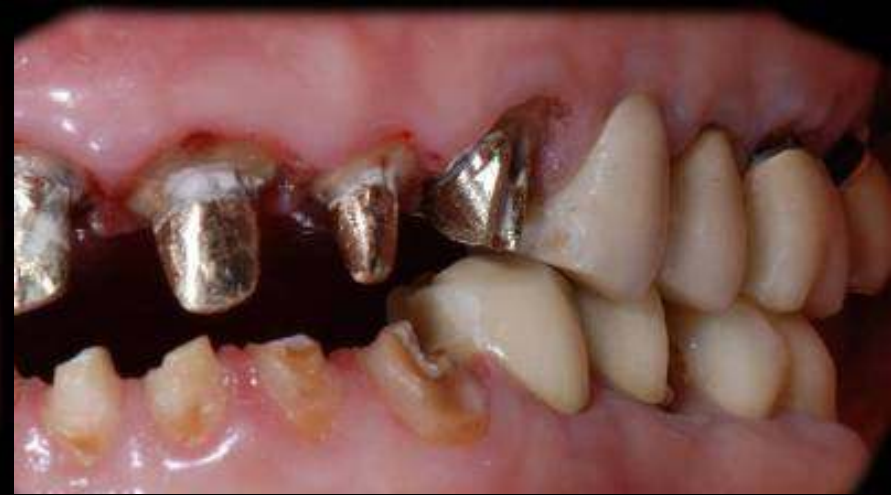
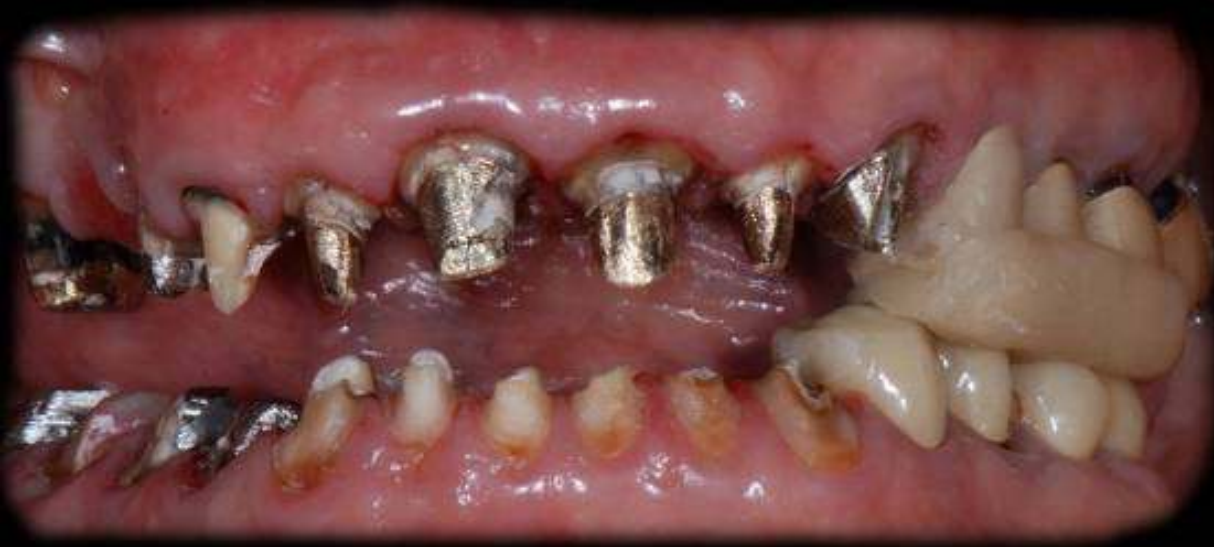


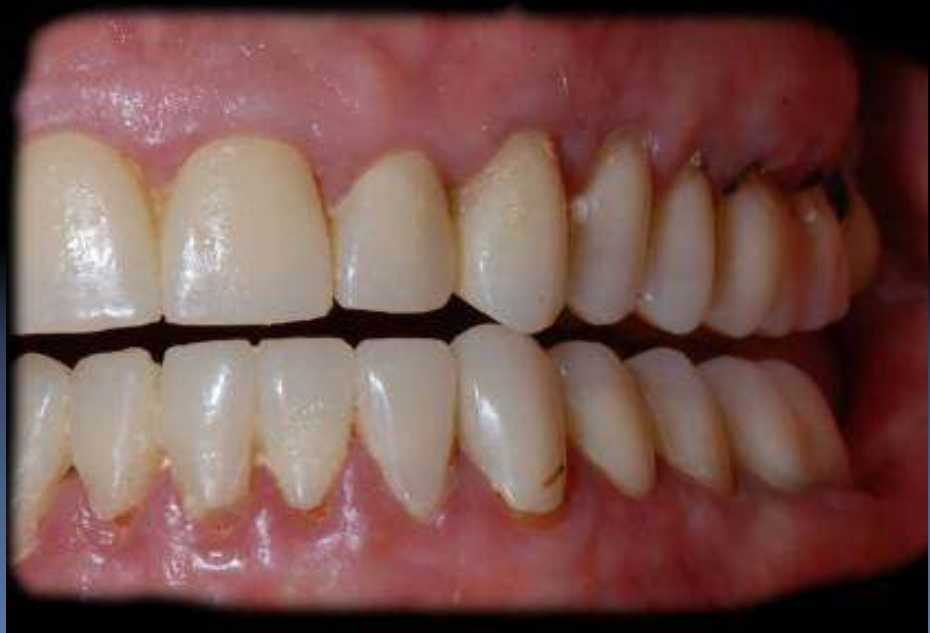
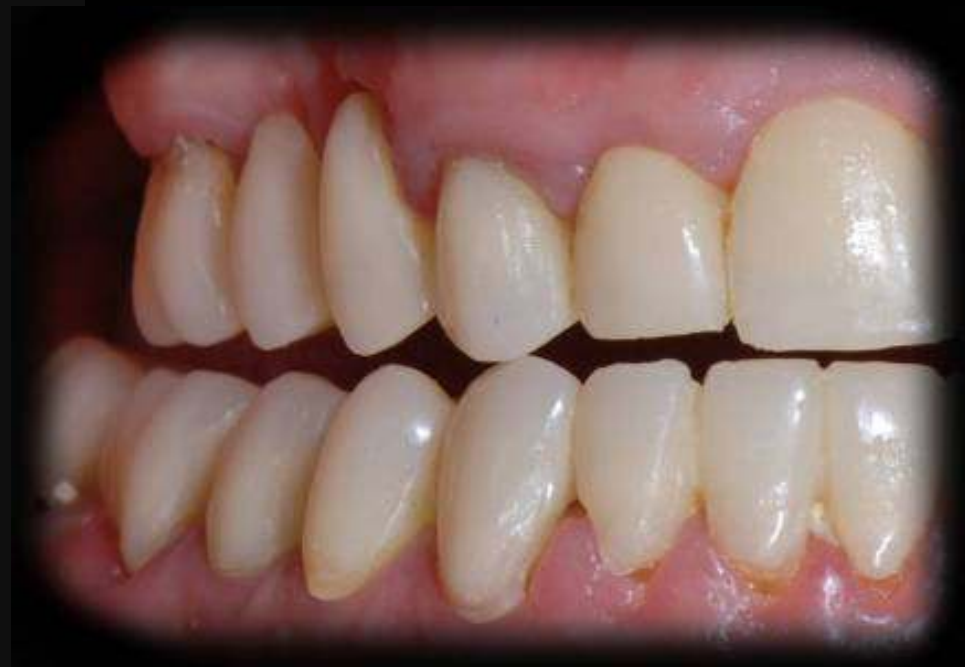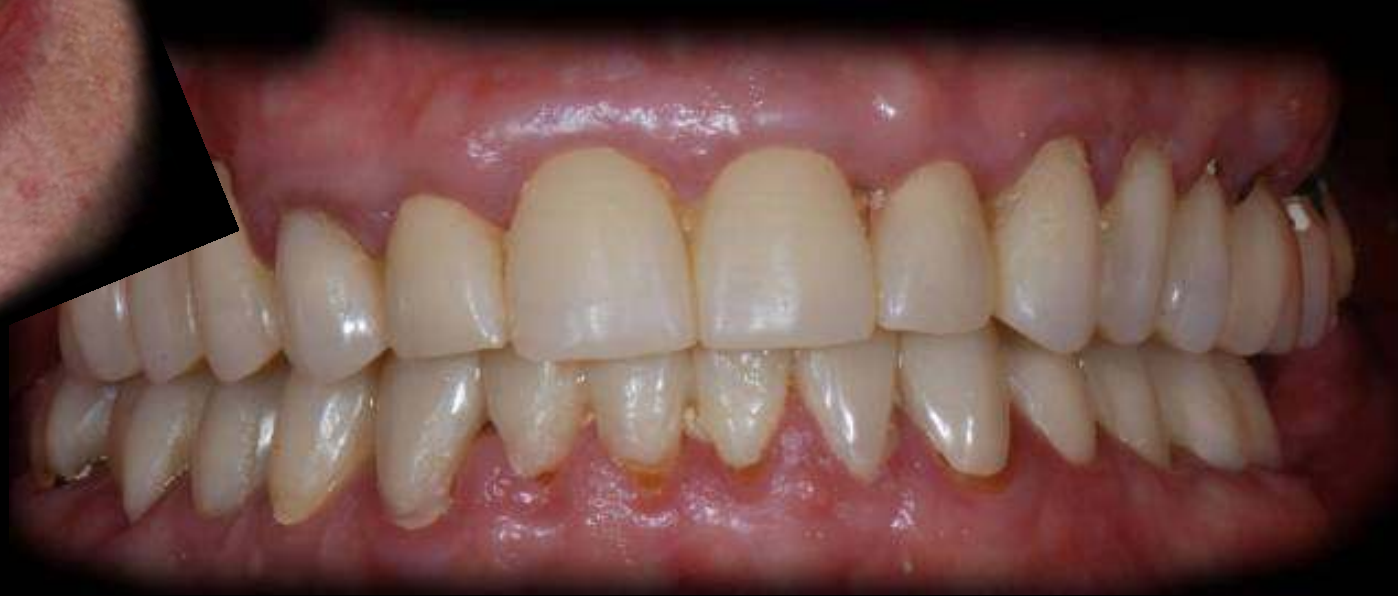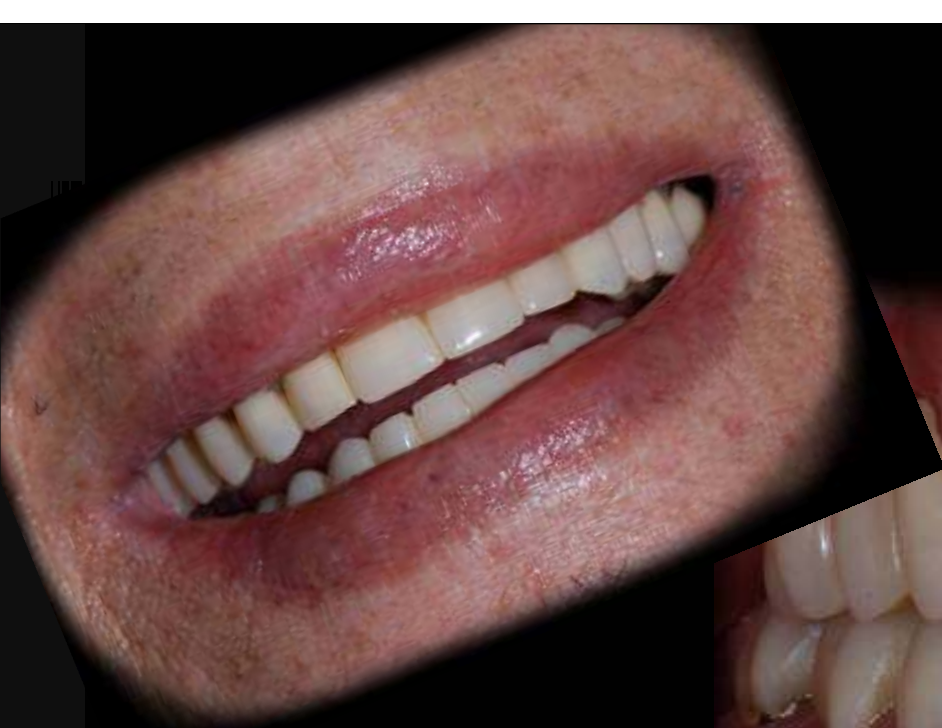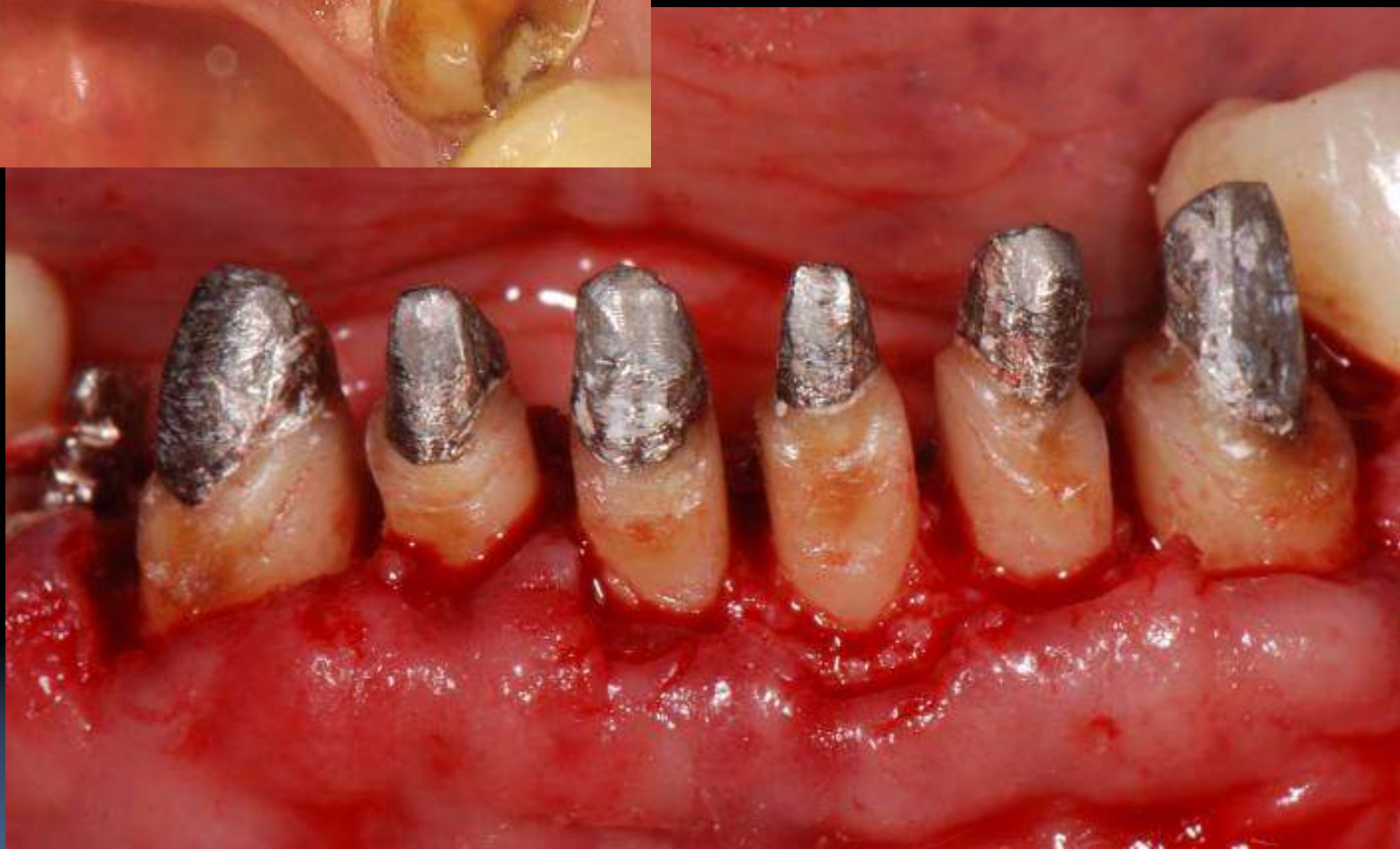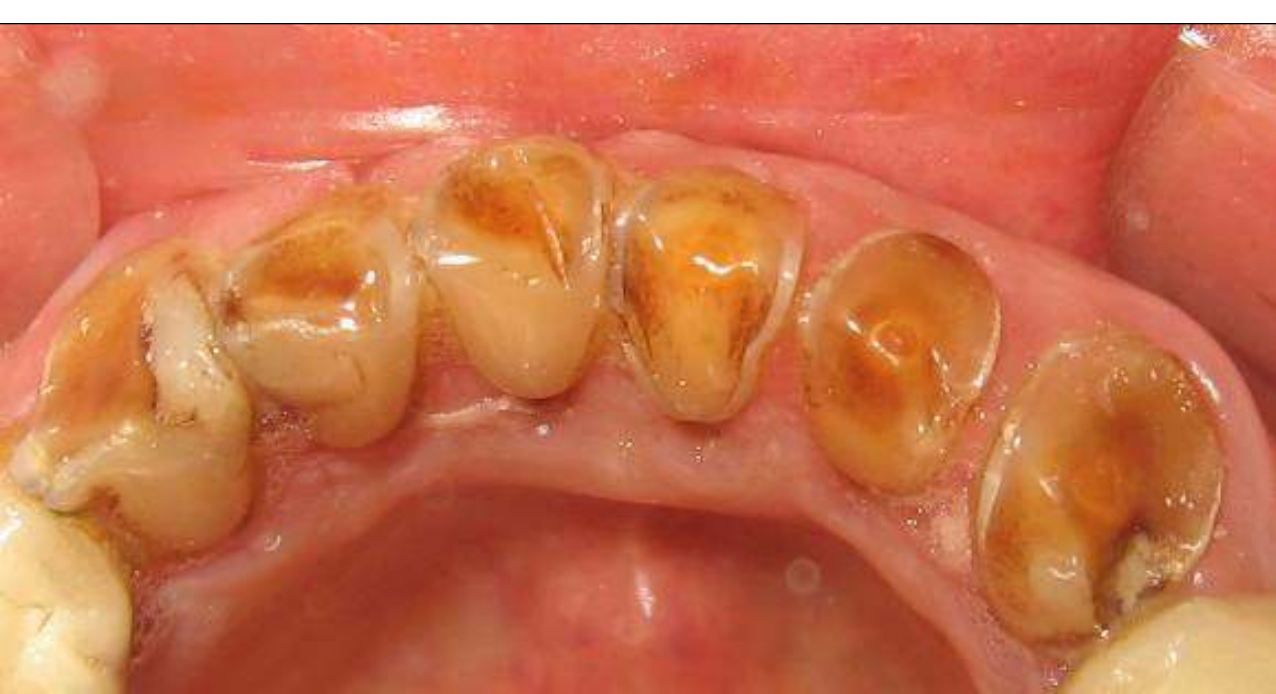Provisórios
Guia



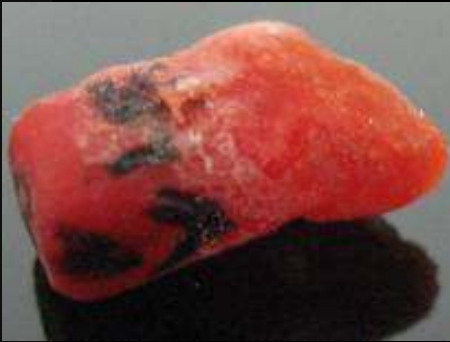






R.A.I.

CF

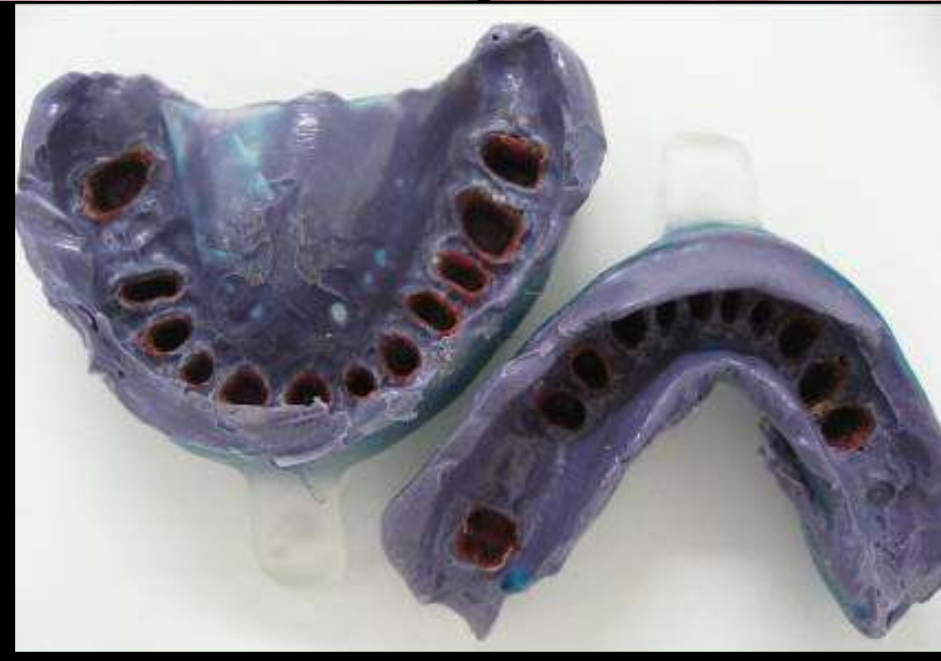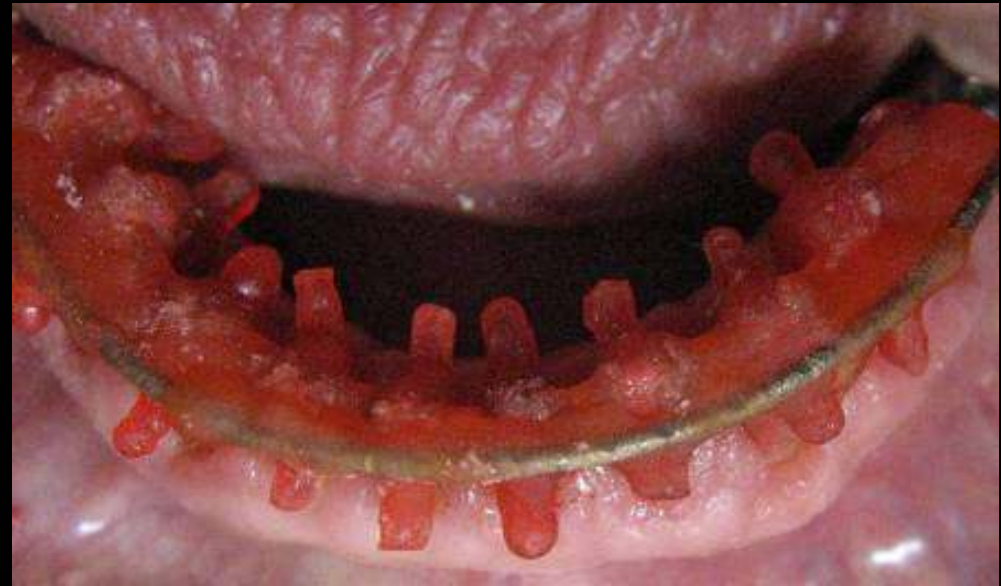
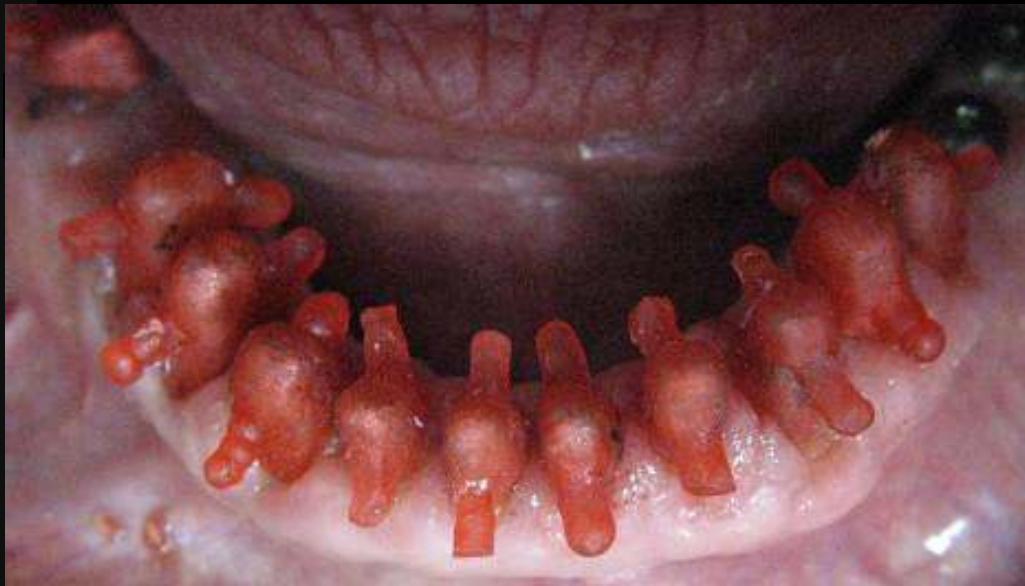


Casquetes para moldagem

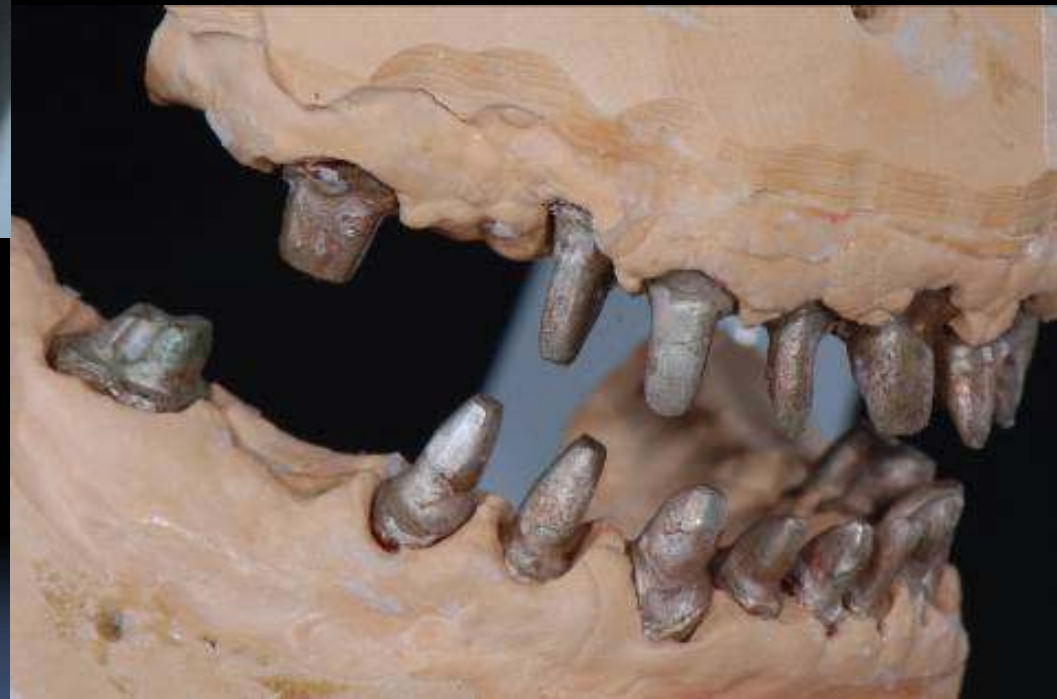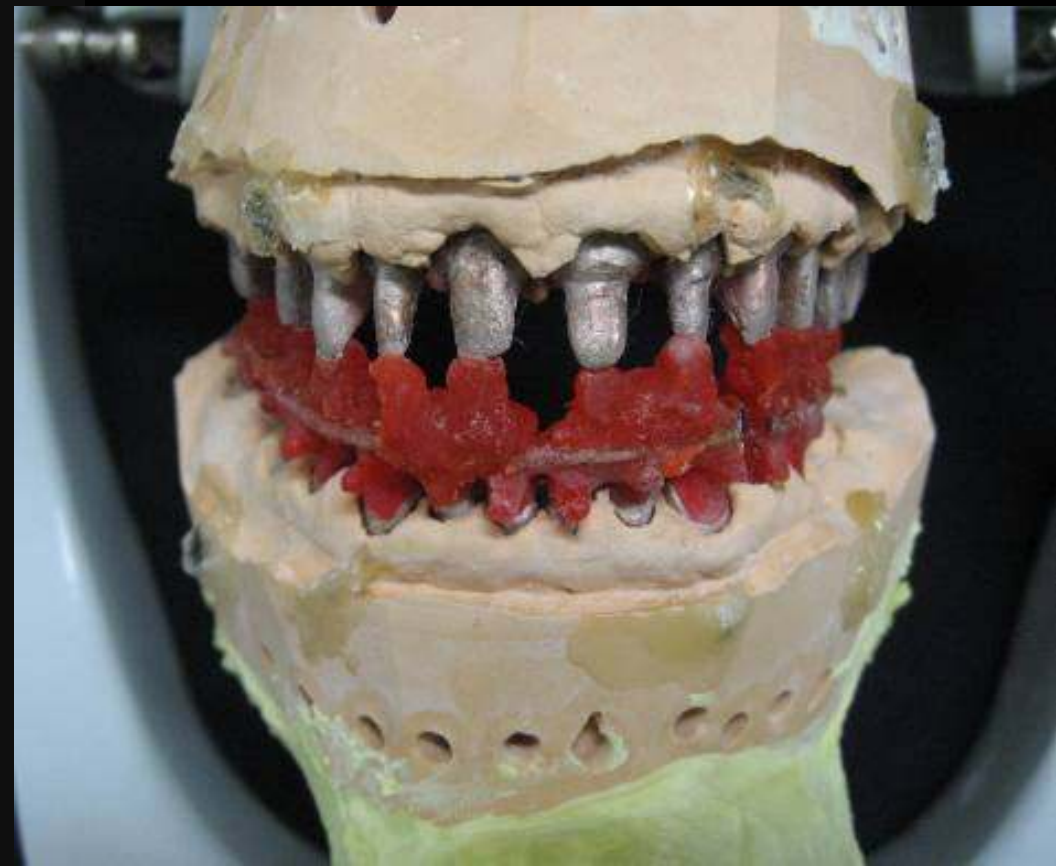


TorquØis metalizados

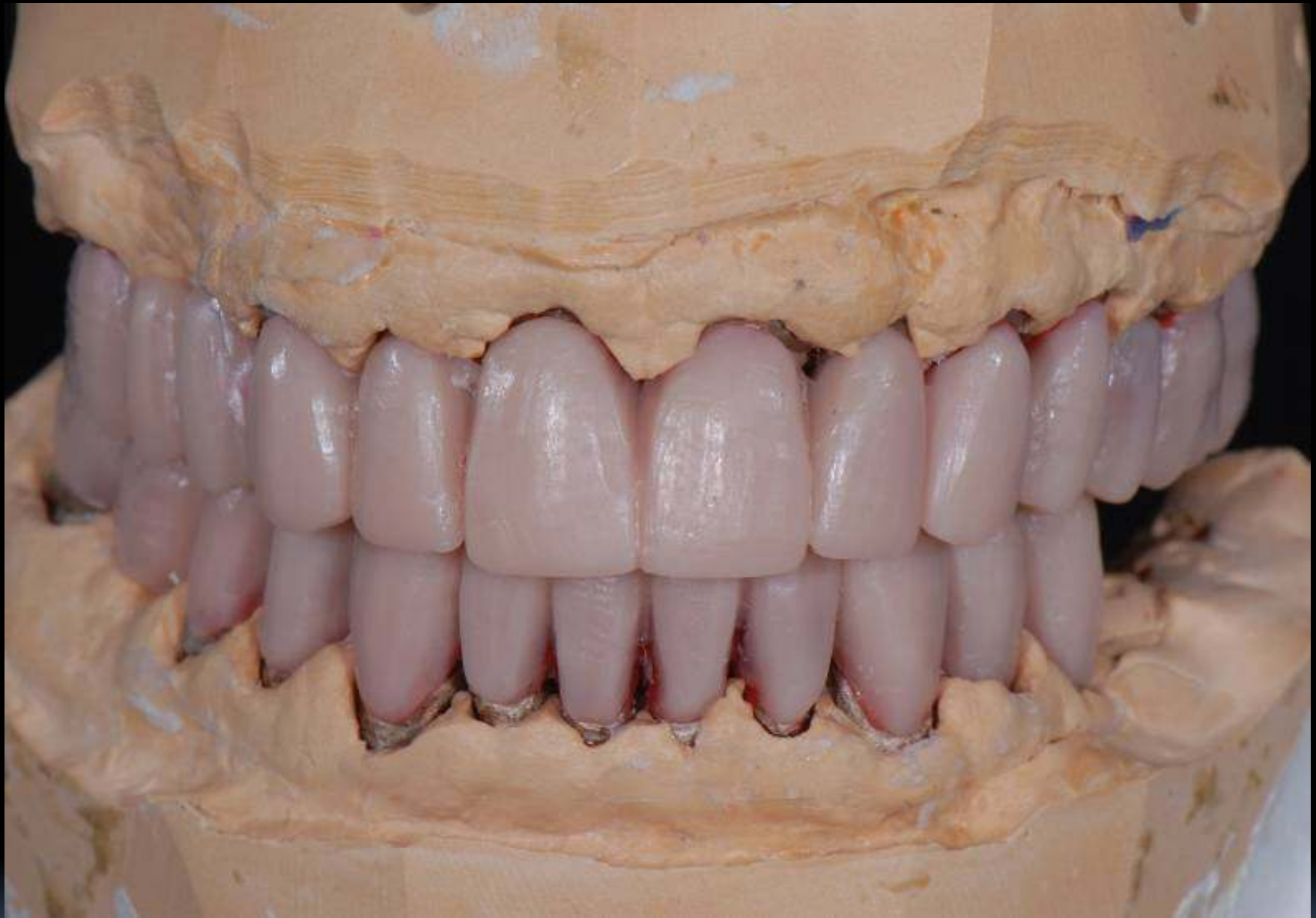Moldagem



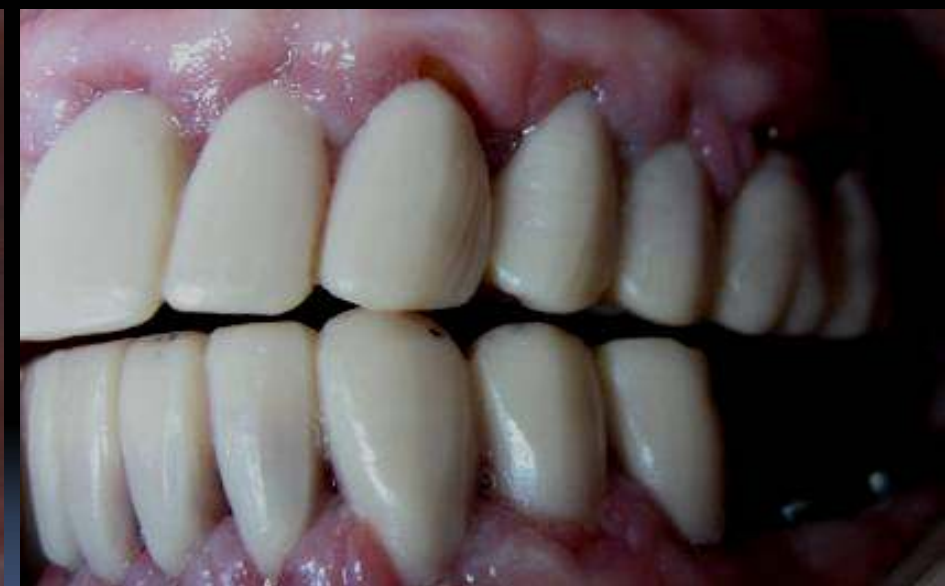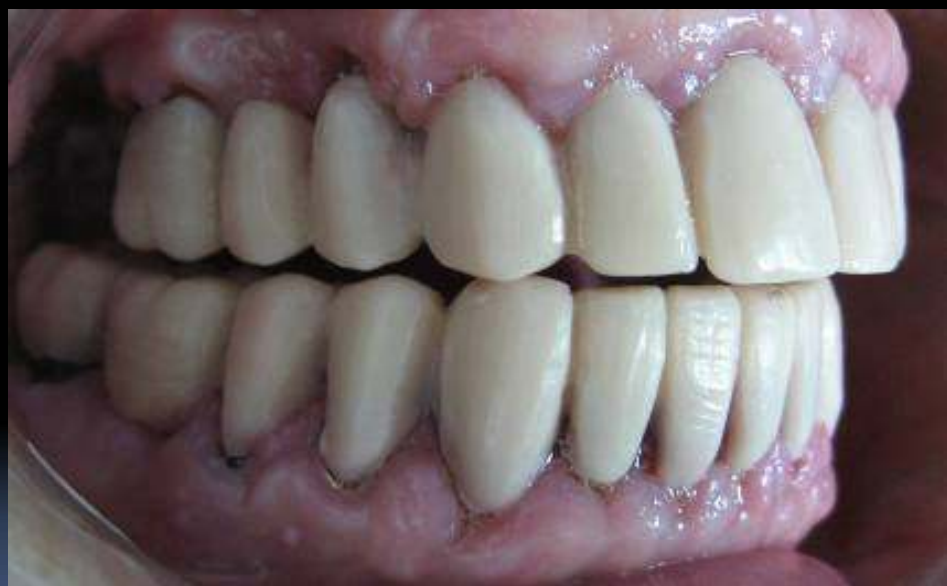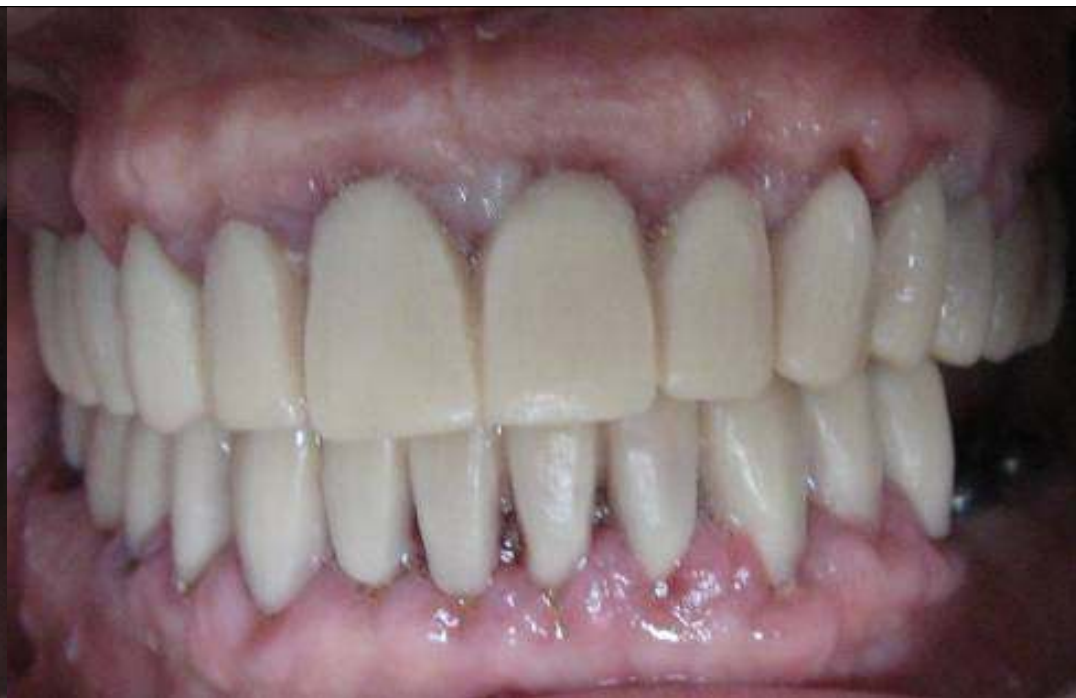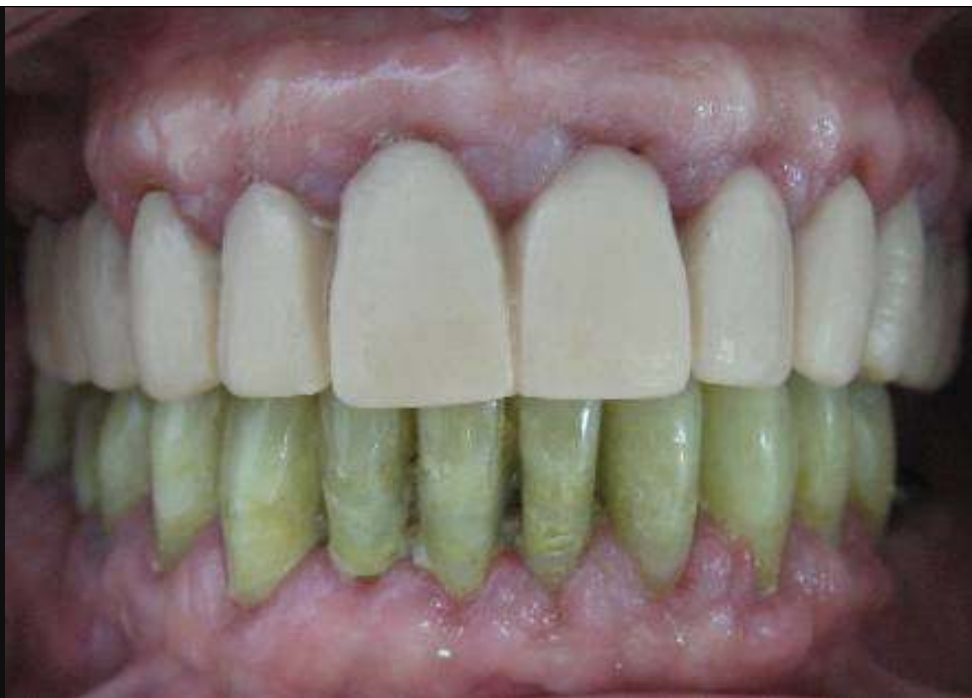Transferenciados casquetes



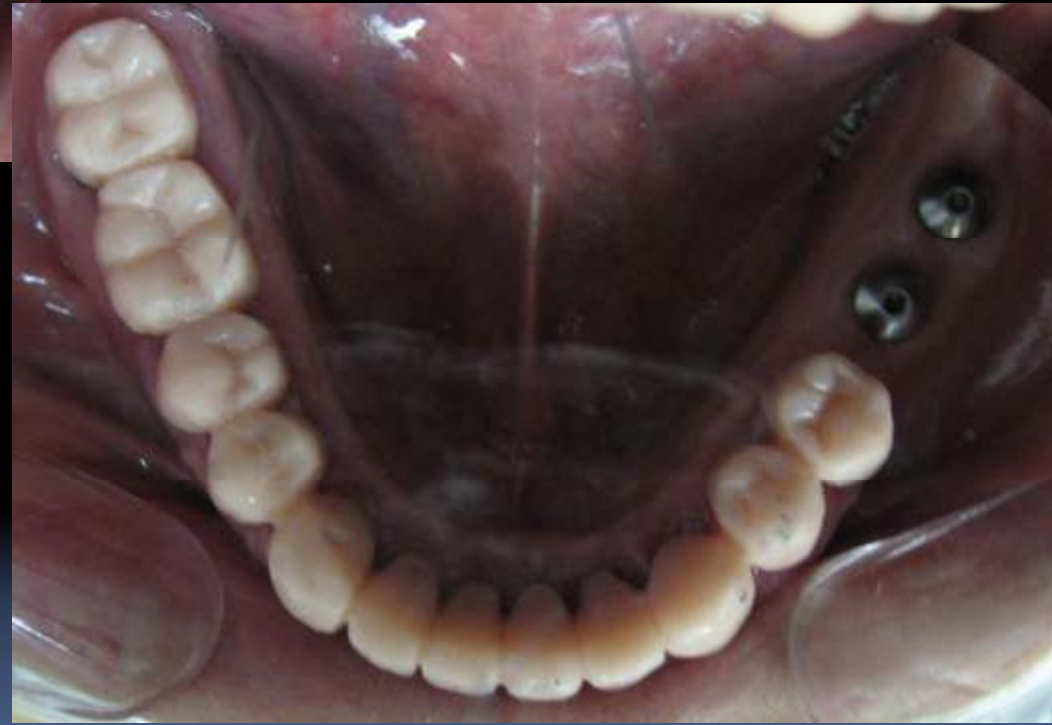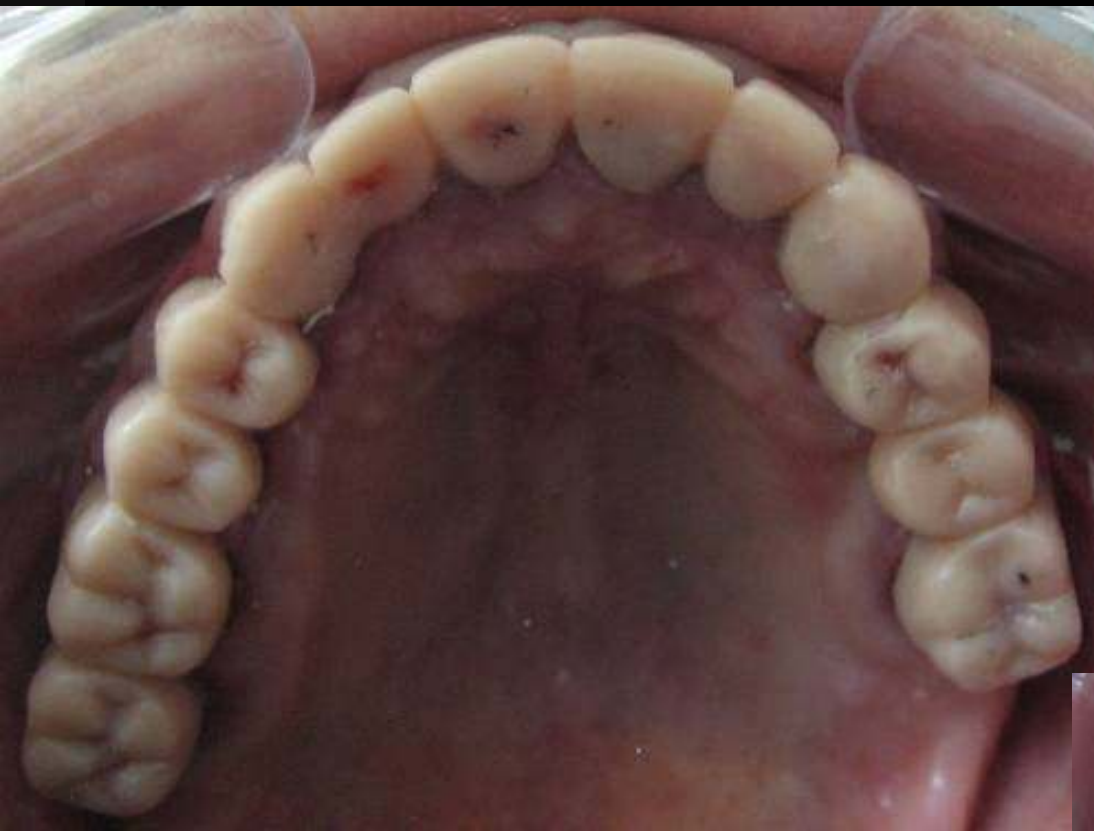Modelocom troqueis



Enceramento

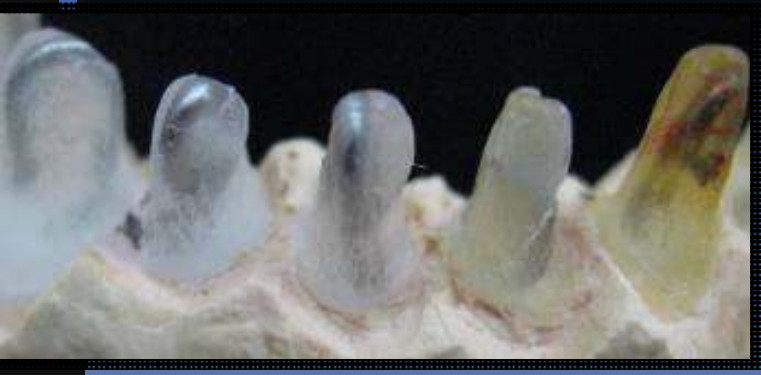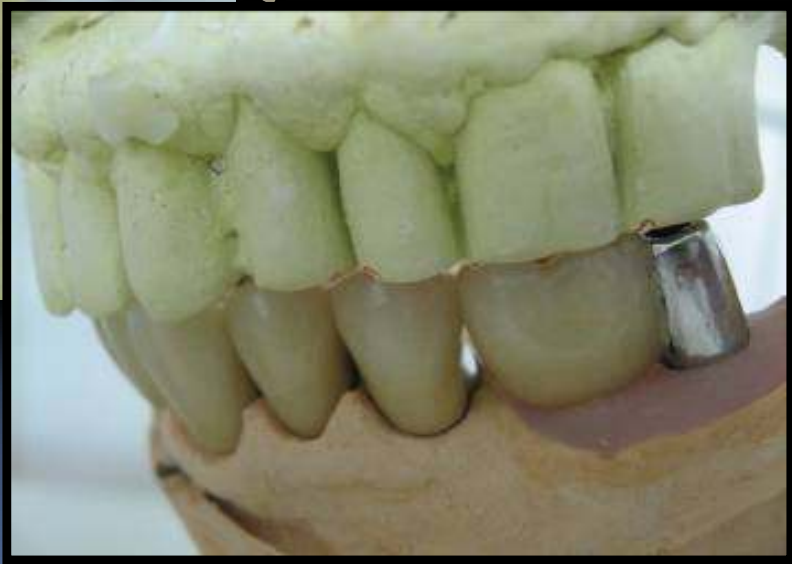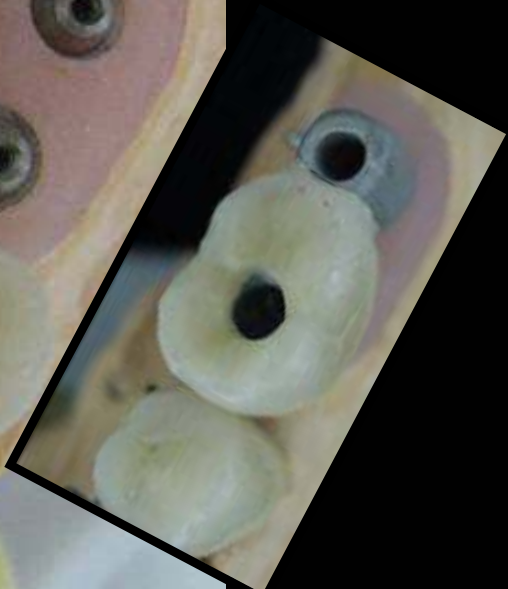


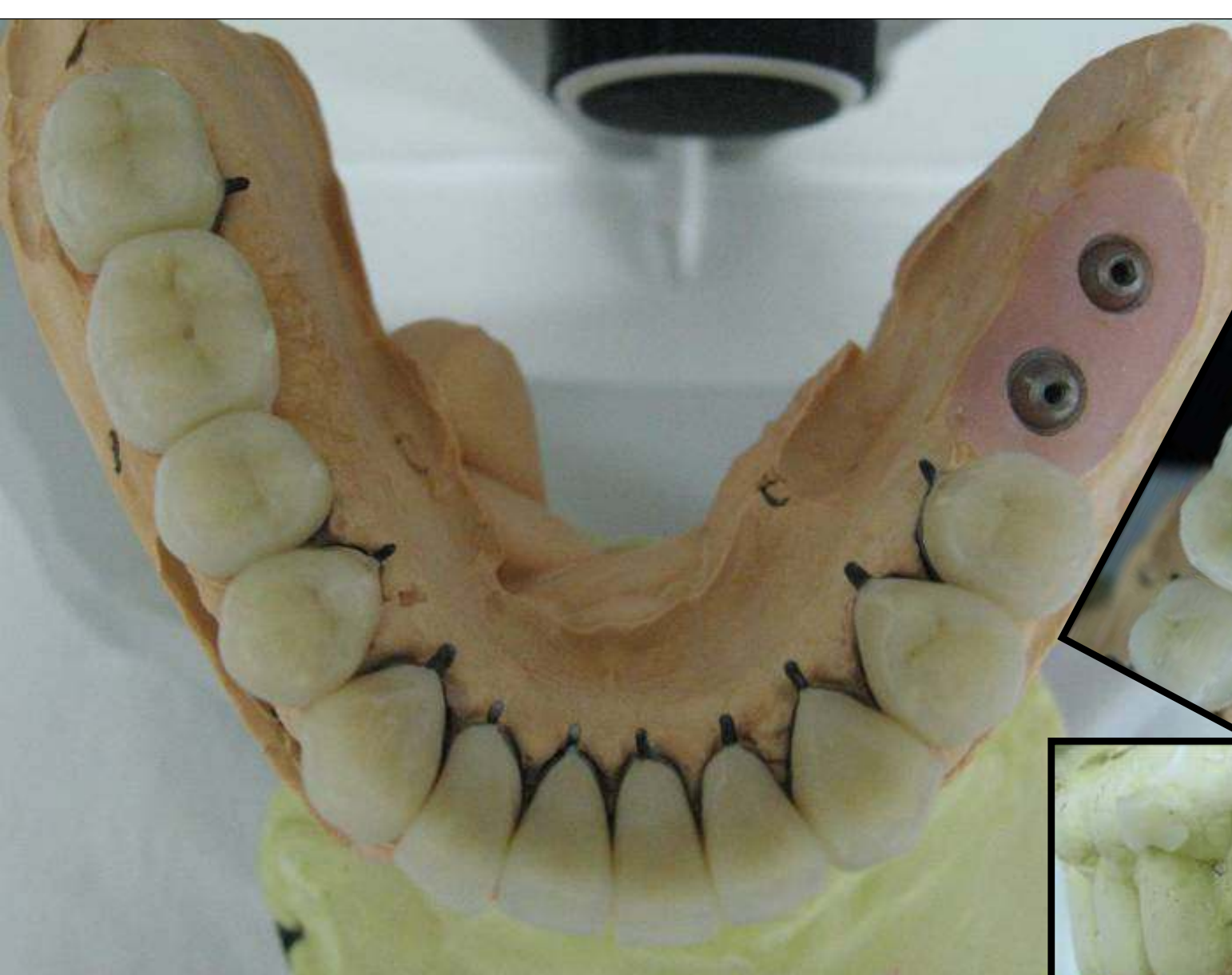Provado Enceramento



Contatos Oclusais-Enceramento

CF



CF







